

## Recent Concepts in Feline Lower Urinary Tract Disease

Roger A. Hostutler, DVM, MS\*,  
Dennis J. Chew, DVM, Stephen P. DiBartola, DVM

*Department of Clinical Sciences, The Ohio State University, College of Veterinary Medicine,  
Columbus, OH 43210, USA*

A clinical description of lower urinary tract disease (LUTD) in cats in 1925 [1] accurately described the clinical signs and the disease, and reported it to be commonplace. The terms *feline urologic syndrome* (FUS) and *feline lower urinary tract disease* (FLUTD) have since been used to describe the constellation of clinical signs related to irritative voiding but do not identify the underlying etiology. Most cats with LUTD have feline idiopathic or interstitial cystitis (FIC), but urolithiasis, bacterial urinary tract infection (UTI), anatomic malformations, neoplasia, behavioral disorders, and neurologic problems (eg, reflex dysnergia) may also occur, although more uncommonly than FIC. Regardless of the underlying etiology, the resultant clinical signs are similar and include dysuria, stranguria, hematuria (macroscopic and microscopic), pollakiuria, and periuria (a word used to refer to urination in inappropriate places).

Obstructive and nonobstructive uropathy are broader concepts that may also be used to classify LUTD by the presence or absence of urethral obstruction, respectively. Obstructive uropathy is rare in female cats and is primarily seen in male cats. The diameter of the urethra and frequency of obstructive uropathy do not differ between castrated and intact male cats, but urethral obstruction occurs with higher frequency in castrated male cats [2].

Diseases of the lower urinary tract are becoming more apparent clinically as indoor cats and multicat households are becoming more common. Inappropriate elimination results in the relinquishment of approximately 4 million cats annually to animal shelters because of behavior that is unacceptable to owners [3]. The estimated prevalence of LUTD in primary care practice in the United States has been reported to be approximately

---

\* Corresponding author.

*E-mail address:* [Hostutler.4@osu.edu](mailto:Hostutler.4@osu.edu) (R.A. Hostutler).

1.5% [4]. Based on referral institution studies of cats presented with nonobstructive urinary tract disease, the two most common causes have been found to be FIC (55%–69%) and urolithiasis (13%–28%) [5,6]. A diagnosis of FIC is made after routine diagnostic tests, including urinalysis, urine culture and sensitivity, radiography, ultrasonography, and contrast radiography, fail to identify an etiology. If uroendoscopy is performed and submucosal petechial hemorrhages (ie, glomerulations) are seen, a diagnosis of FIC is made. This nomenclature is used based on similarities of clinical signs seen in human beings with interstitial cystitis.

Recently, many studies have evaluated the effects of dietary and environmental factors on development of LUTD in cats. The influence of behavioral disturbances and interactions with other cats in development of lower urinary tract signs cannot be overemphasized. Most cats with lower urinary tract signs are presented between 2 and 6 years of age, and the disorder is uncommon in cats less than 1 year of age or greater than 10 years of age. When looking solely at nonobstructive disease, LUTD occurs with equal frequency in male and female cats. The risk is higher for castrated or spayed cats when adjusted for age, but the age of neutering does not seem to be clinically relevant [2].

Body weight and diet have been reported to be risk factors when compared with nonaffected cats. Cats that are obese and sedentary have been shown to have a higher incidence of LUTD, as do cats that are fed solely dry food or fed intermittently throughout the day [2].

Another study found an association with indoor elimination, confinement, and sleeping; recent moves; and decreased water intake with the development of LUTD [7]. Environmental factors, such as interactions with owners, multicat households, and changes in routine, have been associated with LUTD and are discussed in detail later. Regardless of the ultimate manifestations of LUTD, changes in environment, husbandry, and feeding may decrease the recurrence rate. Recurrence rates have been reported to be as high as 45% within 6 months in male cats with obstructive uropathy [8] and 39% within 1 year in cats with nonobstructive uropathy [9].

### **Diagnostic workup**

No clinical sign or combination of clinical signs is diagnostic of a particular LUTD in cats. Making a diagnosis involves integrating findings from the signalment, history, physical examination, clinical signs, time course of the disease, urinalysis with sediment evaluation, urine culture and sensitivity testing, and urinary tract imaging. The modality of imaging chosen may include a combination of plain abdominal radiography, ultrasonography of the urogenital system (which affords minimal urethral evaluation), contrast radiography, and uroendoscopy (including urethroscopy and cystoscopy).

Consideration of the signalment may be helpful in developing a list of differential diagnoses. It would be uncommon (<5%) for a cat older than 10 years of age to develop idiopathic cystitis. Bacterial UTIs are diagnosed in more than 50% of cats older than 10 years of age presented with lower urinary tract signs [10]. Likewise, it would be unusual for a young cat to develop a bacterial UTI. Laboratory evaluation of blood work generally is unremarkable unless other diseases, such as chronic renal failure, are present. If concomitant disease is suspected, a complete blood cell count and serum biochemistry profile should be evaluated.

Periuria is a word that has been coined to describe the tendency of cats with irritative voiding to urinate in places other than the litter box (inappropriate urination). Periuria is the most common clinical sign reported by owners of cats with LUTD, and these cats often are suspected by veterinarians to have a behavioral disorder. Approximately half of cats with inappropriate urination as the only client-reported clinical sign have been reported to have interstitial cystitis diagnosed by uroendoscopy [6]. The time course of the clinical signs also may be helpful in arriving at a diagnosis. Initial bouts of interstitial cystitis generally resolve within 7 days with or without treatment. Other diseases, such as urolithiasis and bacterial UTI, often result in clinical signs that are present for longer periods and may be progressive in severity unless adequate therapy is instituted.

Urinalysis with sediment evaluation should be performed if there is recurrence of clinical signs, evidence of underlying chronic renal failure, or previous urinary catheterization or if a perineal urethrostomy is present. Urine dipstick pads that detect white blood cell (WBC) esterase often are positive in the absence of pyuria in cats (ie, they frequently yield false-positive results). When evaluating feline urine sediment, care must be taken not to overinterpret the presence of bacteria. Cellular debris may exhibit Brownian motion and be misinterpreted as bacteria. Dilute urine in the face of pyuria or significant pyuria (>5 WBCs per high-power field [hpf]) regardless of urine specific gravity (USG) warrants urine culture and sensitivity testing on urine collected by cystocentesis. The presence of crystals in urine sediment may have no clinical importance in cats without a stone or urethral plug, because crystals do not damage healthy urothelium. Urine that has been refrigerated or stored for hours often contains crystals in the urinary sediment, and this phenomenon is exaggerated in urine that is highly concentrated [11].

Plain abdominal radiographs that include the pelvic and penile urethra can be helpful in identifying radiopaque calculi (eg, struvite, oxalate) more than 3 mm in diameter. Contrast radiography, including cystography, urethrography, and urethrocystography, is indicated in cats with recurrent or lingering clinical signs. Contrast cystography often is normal in FIC, but the technique may be helpful in detecting small calculi, radiolucent calculi, urachal diverticula and neoplasia as well as in determining bladder wall

thickness. Occasionally, contrast material may be seen permeating through the bladder wall in severe cystitis. Contrast evaluation of the urethra generally is normal but may be helpful in diagnosing urethral strictures in male cats and stones in the urethra [12,13]. Generally, these procedures are performed simultaneously as a contrast urethrocytogram in male cats, thus maximizing the information the clinician obtains from one procedure.

Abdominal ultrasonography is useful to evaluate the bladder but is unrewarding for evaluation of the entire length of the urethra. Abdominal ultrasonography may detect small calculi, radiolucent calculi, and bladder masses like polyps and neoplasia and may aid in assessing bladder wall thickness if the bladder is sufficiently distended.

Uroendoscopy is a valuable tool in evaluation of cats that have recurrent or persistent clinical signs associated with the lower urinary tract. Uroendoscopy allows visualization of the urethral and bladder mucosa, detection of small calculi not seen on abdominal ultrasonography, evaluation for urachal remnants, and direct visualization of masses that may be present. Uroendoscopy of female cats is performed using a rigid pediatric cystoscope, which affords much greater detail and manipulation than can be obtained with the flexible fiberoptic ureteroscope that is used in male cats. The rigid cystoscope may be used in male cats that have had a perineal urethrostomy performed and allows the clinician to obtain biopsies. The 1.1-mm flexible urethroscope used in male cats is not as optimal for evaluation of the bladder as the 3.0-mm rigid cystoscope, but it is adequate for evaluation of the urethra for the presence of strictures, plugs, spasms, and stones.

Most cases of LUTD in the cat can be managed successfully in primary care practice. Generally, clinical signs resolve within 7 days. If clinical signs persist or recur repeatedly, further diagnostics and referral to an internist or behaviorist may be indicated. If a cat has two or three episodes of lower urinary tract signs within a short period, further imaging and diagnostics, such as uroendoscopy, may be indicated. Veterinary behaviorists can play an important role in evaluation and management of behavioral and environmental factors. Strategies to enrich the environment of the cat and lessen stresses associated with multicat households and indoor living should become a routine part of husbandry of cats (discussed in detail later in section on treatment of interstitial cystitis).

## **Feline interstitial/idiopathic cystitis**

### *Pathophysiology*

Multiple abnormalities of the bladder, central nervous system, and hypothalamic-pituitary-adrenal axis may lead to the clinical manifestations of FIC. The pelvic and hypogastric nerves and their central connections in the dorsal horn of the sacral and lumbar spinal cord provide sensory

innervation to the bladder [14]. Normal bladder urothelium is lined by a specific glycosaminoglycan (GAG) called GP-51 that is believed to inhibit bacterial adherence and protect the urothelium from noxious urine constituents. People and animals with interstitial cystitis excrete decreased amounts of urine GAG [15] and GP-51 [16]. If the GAG layer or urothelium is compromised, constituents of the urine can contact the sensory nerves and result in neurogenic bladder inflammation. The sensory neurons are located in the submucosa and are composed primarily of unmyelinated pain fibers (C-fibers). Once these sensory fibers are stimulated, action potentials are transmitted to the spinal cord and are perceived as pelvic pain. In addition to transmitting the sensation of pain to the brain, local axon reflexes that lead to the release of substance P (SP), a neurotransmitter that results in local potentiation of the inflammation, are released. Local SP release results in increased vascular permeability by means of direct action on vessel walls and through SP-mediated release of inflammatory mediators, such as histamine from mast cells. Receptors for SP also are present on smooth muscle and cause contraction when stimulated. Figs. 1 and 2 illustrate the normal bladder and the described changes that lead to the clinical signs seen with FIC.

Histologic findings in the bladders of FIC-affected cats are typical but not pathognomonic. Changes include edema, hemorrhage, and dilatation of blood vessels in the submucosa. Increased mast cell density has been reported in some cats with FIC when toluidine blue stain is applied [17]. Routine hematoxylin and eosin staining of specimens may reveal an intact or partially denuded urothelium. Electron microscopy, however, has shown areas that lack urothelium and distortion of gap junctions [18]. These findings support the role of local neurogenic inflammation potentially mediated by SP and the findings of other studies on increased bladder permeability in cats with FIC [19].

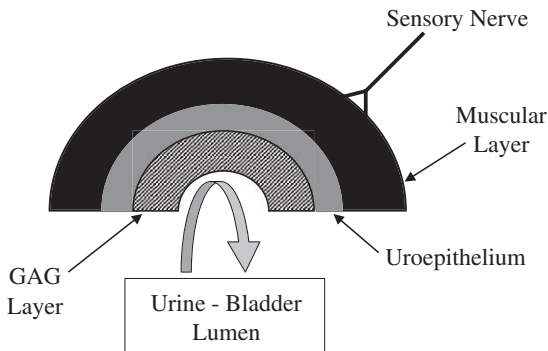


Fig. 1. Normal bladder with intact urothelium and glycosaminoglycan (GAG) layer. The urothelium and GAG act as a natural barrier to protect the underlying layers and sensory nerves from the noxious urine.

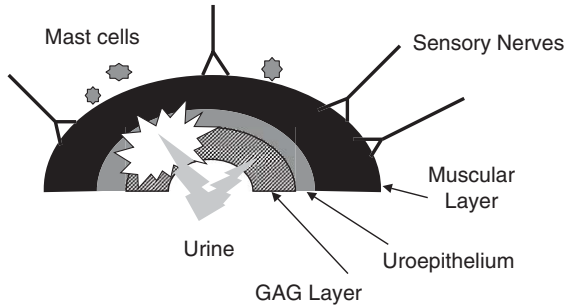


Fig. 2. Schematic of bladder of cat affected with feline interstitial cystitis (FIC). This demonstrates loss of integrity of the glycosaminoglycan layer and urothelium. Loss of integrity of these layers leads to recruitment of sensory nerves, recruitment and activation of mast cells, and changes in the central nervous system that lead to the clinical signs seen with FIC.

The overall clinical manifestations and high recurrence rates in cats with FIC also seem to involve intimate changes in the neurochemistry of the brain. The locus coeruleus (LC) [20] and paraventricular nucleus [21] recently have been reported to be involved in the pathogenesis of FIC. The LC is responsible for excitatory stimulation to the bladder and is activated on bladder distention [22]. These areas in cats with FIC recently have been reported to possess increased tyrosine hydroxylase immunoreactivity, suggesting increased catecholamine synthesis [20,21]. Affected animals also have increased concentrations of circulating catecholamines [23] at rest and during stressful situations.  $\alpha_2$ -Adrenoceptors also seem to play a role in the development of FIC in cats. Centrally,  $\alpha_2$ -adrenoceptors are found in the LC and spinal cord, where they inhibit catecholamine release and pain input to the brain, respectively [24,25]. Peripherally,  $\alpha_2$ -adrenoceptors are found in the bladder mucosa, where they are believed to regulate blood flow. Desensitization of the central  $\alpha_2$ -receptors as a result of chronic stimulation and enhanced catecholamine release from the bladder of cats with FIC has been reported [26] and may result in potentiation of the inflammatory response. Finally, cats with FIC have been shown to have a suboptimal response to exogenous corticotropin stimulation when compared with control cats [27], decreased adrenal volume when evaluated by CT [28], and a histologically greater adrenal medulla area than normal cats. These findings suggest that FIC results in overactivation of the sympathetic nervous system with suboptimal activation of the hypothalamic-pituitary-adrenal axis.

### Diagnosis

The terms *idiopathic cystitis* and *interstitial cystitis* often are used interchangeably. Idiopathic cystitis is the most common diagnosis in cats with lower urinary tract signs. The term *idiopathic cystitis* is used if all

diagnostics fail to confirm the presence of another disease, such as urolithiasis or a bacterial UTI. Idiopathic cystitis generally is seen in middle-aged cats and is rarely diagnosed in cats older than 10 years of age, and no gender predisposition has been reported in cats with nonobstructive FIC [7]. No clinical signs are specific for FIC, but owners of affected cats most commonly report periuria. Cats may exhibit solely periuria, or they may also show signs of pollakiuria, stranguria, and hematuria.

Results of radiography and urinalysis often are nonspecific in cats with FIC. Abdominal radiography may be performed to aid in the elimination of urolithiasis as a differential diagnosis in cats with multiple recurrences of clinical signs. Double-contrast cystography and positive-contrast urethrography are recommended for cats with recurrent lower urinary tract signs in which no cause has been found on urinalysis, urine culture, and plain abdominal radiographs. Results from cats with FIC are normal in approximately 85% of the cases. Focal or diffuse thickening of the bladder wall is seen in some, and contrast agent may be observed dissecting through the bladder wall in a few cases [13]. Ultrasonography is less invasive than urethrocytography but is less sensitive in the detection of small lesions and provides little information about the urethra.

Urinalysis may identify hematuria and proteinuria, the severity of which can vary substantially throughout the day or over the course of several days. The absence of hematuria does not exclude a diagnosis of FIC. A paucity of WBCs is found in the urine sediment. Crystalluria is variable and of no pathologic significance in cats with FIC. Often, crystalluria is an artifact of refrigeration and time of storage. Many times, bacteria are reported from the laboratory when, in fact, they are not present. This problem is common in the cat and is caused by particulate material (eg, small crystals, cellular debris, lipid droplets) that exhibit Brownian motion and may be misidentified as bacteria. The results of urine cultures in cats with FIC are negative (ie, no growth or <1000 colony-forming units/mL on urine collected by cystocentesis). USG should be greater than 1.025 in cats eating canned foods and greater than 1.035 in cats eating dry foods. Urinalysis findings, however, are not specific for any one LUTD. Fig. 3 shows typical urine sediment found in cats affected with FIC.

If clinical signs are continuous or frequently recur or if the episodes become more severe, direct visualization of the lower urinary tract using uroendoscopy may be indicated to eliminate other differential diagnoses and to confirm the diagnosis of FIC. If uroendoscopy is performed and submucosal petechial hemorrhages (ie, glomerulations) are seen, the term *interstitial cystitis* is appropriate (Fig. 4). Glomerulations are not seen in all cats with FIC and may be seen in some sensitive asymptomatic cats that have undergone recent stress [29]. Other findings on cystoscopy in cats with FIC include edema, debris in the lumen of the bladder, and increased vascularity. The severity of cystoscopic lesions does not seem to correlate with the severity of clinical signs observed by the owner; therefore,

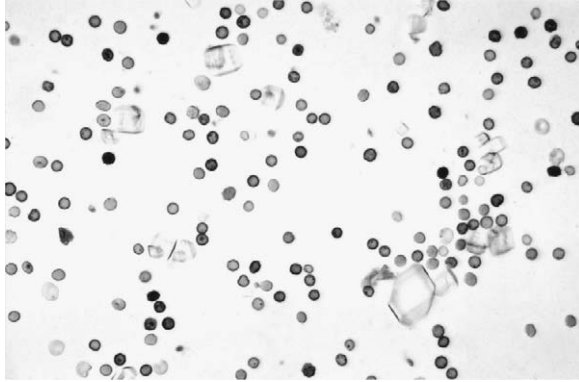


Fig. 3. Urine sediment of cat affected with feline interstitial cystitis. Notice the presence of red blood cells, with a paucity of white blood cells. The presence of crystalluria does not indicate that they are the cause of the clinical signs. A normal urothelium should not be adversely affected by their presence.

cystoscopic re-evaluation of the bladder is not routinely performed once a diagnosis of FIC is made.

FIC is a diagnosis of exclusion, and diagnostic tests must be chosen with the signalment, history, and clinical signs in mind. A young cat with clinical signs lasting 5 to 7 days most likely has FIC. With increasing frequency or severity of episodes, more invasive diagnostics are warranted, however.

### *Treatment*

Treatment of FIC may include environmental enrichment, dietary alterations, pheromone therapy, and pharmacologic intervention in refractory cases. In treating FIC, the owner must be made aware that his or her cat has

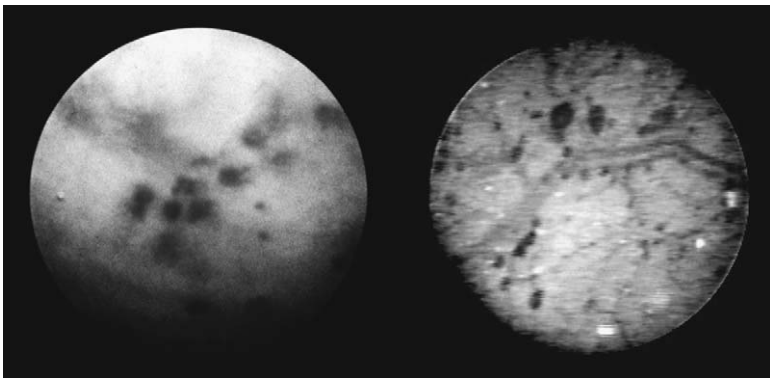


Fig. 4. Cystoscopic evaluation of the urinary bladder in cats affected with feline interstitial cystitis. The figure on the left depicts a cat with multiple large glomerulations. The figure on the right depicts multiple smaller glomerulations with increased vascularity.



a disease with an unknown cause and with no known cure and that the goal of therapy is to decrease the severity and recurrence rate of episodes. Successfully managing affected cats takes a dedicated and understanding owner and equally dedicated veterinary staff.

Environmental enrichment and modification can reduce stress and decrease the severity and intervals of FIC episodes. These changes often are used as initial treatments before other modalities are attempted. Environmental modification includes changes in management of litter boxes, food dishes, and water bowls. To be optimally appealing to the cat, the litter box should be viewed as its own “plastic palace.” The litter boxes of cats with FIC should be cleaned frequently. Nonclumping unscented litter is preferred by most cats, but a variety of litter types and depths may be offered in separate boxes [30]. Litter boxes should be totally emptied and cleaned weekly to avoid buildup of odors, such as ammonia. The litter boxes also should be placed in an area that is free of intrusion by other pets and children and should not be placed in high-traffic areas or next to an appliance that may suddenly make noise and disturb the cat. Some cats prefer boxes of different sizes and may not prefer boxes that are covered [31]. An adequate number of litter boxes also is important. The “1 + 1” rule states that there should be one more litter box in the house than there are cats. Perhaps just as important as litter box management is adequate cleaning of areas where inappropriate urination has occurred. Inadequate cleaning may attract affected and nonaffected cats to the area despite adequate litter box management.

Environmental modification also may extend to the manner in which food and water are provided to the cat. To ensure adequate water intake, the cat’s water bowl preferences should be determined. Depth of water, type of bowl, flavoring, and the use of fountains all may need to be adjusted until the individual cat’s preferences are determined. The type of food that is fed also should be evaluated. Affected cats should be fed moist food exclusively if accepted by the cat. Some cats accustomed to dry food may refuse moist food, however. If a change in diet is attempted, the new food should be introduced alongside the current diet in a separate dish. As with litter boxes, food and water bowls should be cleaned with a mild detergent regularly. The 1 + 1 rule used for litter boxes may be extended to food and water bowls, especially in multicat households. This practice may decrease competition for food and water and decrease stress, which may exacerbate FIC.

Environmental enrichment is designed to simulate activities that are natural and enjoyable to the cat. The environment should afford the cat opportunities to climb, scratch, hide, and rest undisturbed. Providing cats with raised walkways, climbing trees (Fig. 5), window seats, and tents can simulate these activities [32]. Simulating natural hunting behavior by the use of laser pointers, hiding food throughout the house, providing a variety of toys, and using containers or toys that intermittently release food during play serves this purpose well [33].



Fig. 5. Environmental enrichment and play with owners are often helpful in cats affected with feline interstitial cystitis. Interactions and enrichment that simulate natural behavior, such as climbing, hunting, and jumping, seem to be helpful.

Interactions of the affected cat with the owners also may aid in reducing stress unless the owner is the source of perceived stress. Some cats enjoy being petted and groomed, whereas others enjoy play interactions with the owner [34]. Especially sensitive cats may perceive any change in routine, feeding schedule, owner work schedule, addition or removal of people or pets from the household, and the owner's emotions as stressful. Therefore, changes in the environment of a sensitive cat should be kept to a minimum.

Dietary modification also may be instituted for animals during their first or second episode of FIC. Attempts to acidify urine and minimize struvite crystalluria often are misguided. No available evidence supports the notion that struvite crystalluria damages normal urothelium or worsens existing cystitis. Perhaps more important is maintaining the constancy, consistency, and composition of the diet that is being fed.

Constancy refers to minimizing changes in the diet that is being fed. If a change in diet is deemed advisable, it should be the cat's choice to switch to the new diet. For example, if a change is made from dry to moist food, both diets should be made available during feedings. If the cat chooses the moist diet, the dry food can be slowly removed as a choice. Consistency refers to the water content of the food. In one report, cats fed a canned

formulation of a food had only an 11% recurrence of signs over a 1-year period, whereas cats fed the dry formulation of the same food had a 39% recurrence rate over the same period [35]. Feeding a canned formulation increases the amount of water the animal is consuming and decreases USG. As a result, the concentration of potentially noxious substances in urine is reduced. Composition refers to the nutrient content of the diet being fed. Feeding of certain diets may result in excretion of noxious substances in the urine. Highly acidic urine may activate sensory nerve fibers in the urothelium. The optimal diet for cats with FIC has yet to be determined, and no commercially available cat foods are specifically designed for the treatment of FIC.

Recently, a synthetic formulation of feline facial pheromone (Feliway; Abbott Laboratories, Abbott Park, IL) has been developed to decrease anxiety-related behavior in cats, including urine marking and destructive scratching. This product also may have salutary benefits for cats with FIC, but such effects have not been reported. One report suggested different behavior in hospitalized cats exposed to Feliway compared with placebo-treated cats [36]. Other reports show reduced urine marking during Feliway treatment, which may be a consequence of reduced vigilance of the cats, because perception of their environment has been favorably altered [37,38]. Although not specifically studied, reduced vigilance likely is related to reduction in activation of the sympathetic nervous system. The use of Feliway may be justified in cats with FIC to reduce the impact of an activated sympathetic nervous system on the disease process. Feline facial pheromone often is used in combination with environmental enrichment to decrease stress in cats with FIC. Feliway is available as a spray form and, more recently, as a room diffuser. The diffuser form is reported to cover approximately 650 sq ft and lasts for approximately 30 days. The spray form is formulated in an ethanol vehicle and may be sprayed in carriers approximately 15 minutes before transport, sprayed in cages in a veterinary hospital, or sprayed on areas of inappropriate elimination in the house.

Drug therapy may be indicated if environmental enrichment and modification in combination with dietary modification, enhanced water turnover, and feline facial pheromone use do not control clinical signs. Long-term drug use is reserved for the most severely affected cats that have persistent clinical signs or those that have multiple episodes of FIC. Cats suffering from a current bout of FIC usually are treated with systemic analgesics. Nonsteroidal anti-inflammatory drugs, such as carprofen and ketoprofen, and potent analgesics, such as opioids, including butorphanol, buprenorphine, and fentanyl, seem to be beneficial in short-term pain relief. Scientific evidence to support their routine use in cats with FIC is lacking, however.

Amitriptyline is a tricyclic antidepressant that has been reported to have benefit in the outcome of cats with FIC that is chronic and has failed other more routine treatments [29]. Unfortunately, this study was not blinded, and

no placebo group was included. Amitriptyline has many effects. It provides analgesia by decreasing C-fiber sensory nerve fiber transmission in the bladder, inhibits norepinephrine reuptake in the LC with subsequent downregulation of norepinephrine outflow, potentially inhibits nociceptive neurons in the spinal trigeminal nucleus, inhibits serotonin reuptake, stabilizes mast cells, blocks glutamate receptors and sodium channels [39], and may have anticholinergic effects. Amitriptyline was not effective in short-term treatment of acute FIC in two recent studies [40,41]. In one study, clinical signs of FIC were worse in cats treated with amitriptyline, possibly as a result of abrupt withdrawal of treatment after 7 days [40]. Extending the duration of therapy may have beneficial effects, however. The severity of clinical signs in severely affected cats treated with amitriptyline at a dose of 10 mg daily was dramatically reduced in 60% of affected cats 1 year after starting therapy. Because of the potential for hepatotoxicity in people, serum biochemistry should be evaluated before and 1 month, 2 months, and 6 months after starting amitriptyline. Other adverse effects include urine retention as a result of anticholinergic effects. In the authors' experience, low doses of amitriptyline often are used with promising results. The dosage range is 2.5 to 12.5 mg given orally once daily. A typical starting dose is 5 mg daily, which is effective in many cats. The dosage may be slowly increased until a calming effect is seen in addition to resolution of clinical signs. If no favorable results are seen after approximately 4 months, the drug should be gradually tapered and discontinued. Other medications that have been used for FIC in cats include clomipramine, fluoxetine, and buspirone. Oral diazepam is not recommended because of its potential to cause hepatic necrosis after oral administration in cats [42]. Glucocorticoids have not been shown to lessen clinical signs or hasten recovery in cats with FIC.

Oral GAG replacement has been used in people with interstitial cystitis with minimally favorable results. Theoretically, orally administered GAG is excreted in the urine and attaches to the defective urothelium, leading to decreased bladder permeability and less neurogenic inflammation. Elmiron (pentosan polysulfate, 100-mg capsules) has been used in human patients with IC. No evidence is available in veterinary medicine to indicate that such replacement decreases the severity or recurrence rate of FIC. GAG replacements, however, can be considered for treatment of cats with severe cystitis in conjunction with other treatments. Adverse effects have not been observed with pentosan polysulfate when given to cats at a dose of 50 mg twice a day. Overdosage theoretically could result in coagulation abnormalities because of the anticoagulant effects of glycosaminoglycans. Adequan (polysulfated glycosaminoglycan) and Cosequin (chondroitin sulfate) are used by some practitioners for treatment of FIC in cats, but such use is off label and no reports document the effectiveness of these treatments. Fig. 6 depicts an approach to diagnosing and treating cats that have recurrent episodes of LUTD.

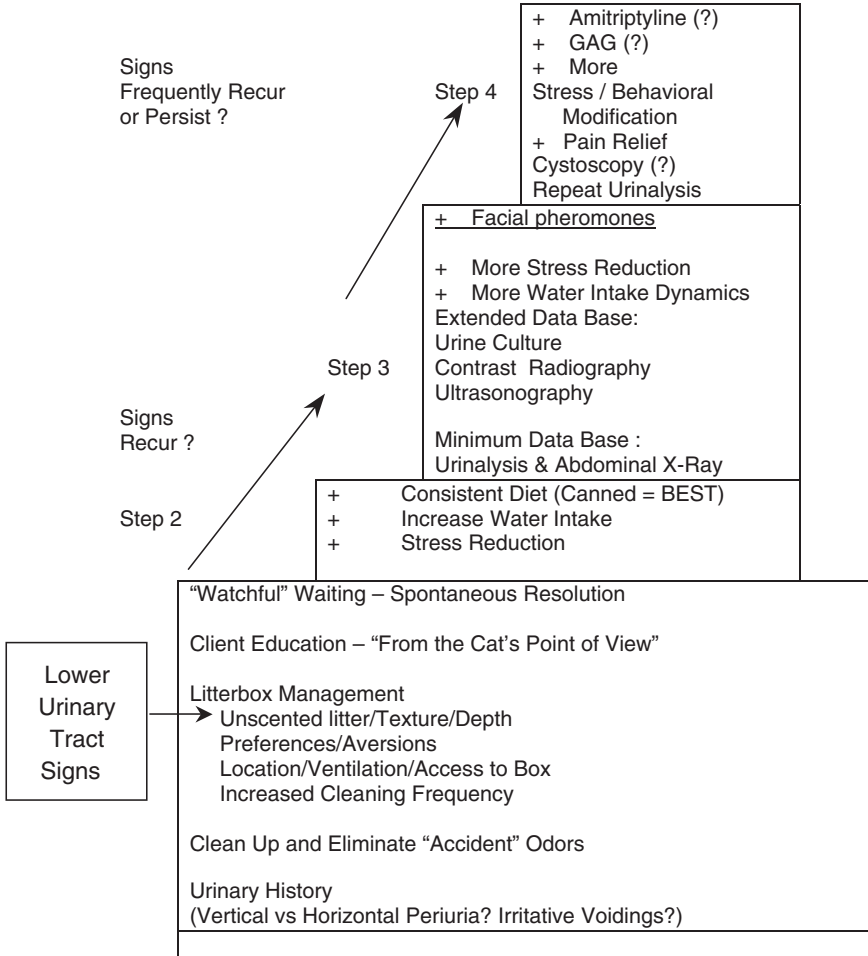


Fig. 6. Stepwise approach to treatment of cats with idiopathic lower urinary tract signs. More diagnostics should be performed when cats fail to clear their initial lower urinary tract signs spontaneously and when signs recur to ensure that the diagnosis is really idiopathic lower urinary tract disease. Properly controlled clinical trials may provide better approaches to treatment in the future, but this is what we do in the interim.

**Urinary tract infections**

Bacterial UTIs are relatively rare in cats. In younger cats, bacterial UTIs affect less than 2% of cats presented for evaluation of LUTD [6]. In cats older than 10 years of age presented for evaluation of lower urinary tract signs, the probability of bacterial UTIs increases to greater than 50%. Cats that have recurrent UTIs were initially suspected to have reinfection based on results of susceptibility antibiograms. More recently, it seems that cats

with recurrent UTIs and chronic renal failure suspected of having reinfections actually have relapsing infection based on genetic analysis of the bacteria [43]. Cats that have a concurrent disease, such as diabetes mellitus or chronic renal failure [10,44], are at increased risk for developing a bacterial UTI. Cats that have recently had a urinary catheter placed for obstructive uropathy or other reasons and cats that have had a perineal urethrostomy performed also are at increased risk of developing a UTI. In such cases, culture and sensitivity of urine obtained by cystocentesis is a more important diagnostic consideration at first presentation.

Urinalysis with sediment evaluation may be helpful but should not be used alone to definitively diagnose UTI. As mentioned previously, identification of “bacteria” in feline urine sediment is problematic, because cellular debris commonly found in the urine sediment exhibits Brownian motion and can easily be misinterpreted as bacteria. The presence of dilute urine (USG <1.030) increases the index of suspicion that a UTI may be present. Also, the presence of WBCs is not diagnostic of a UTI, but it increases the index of suspicion. Pyuria may be present with many LUTDs, including FIC, without a concomitant bacterial UTI. Some cats with a confirmed UTI do not have obvious pyuria, especially when the UTI occurs in association with dilute urine.

If a cat is definitively diagnosed with a UTI based on quantitative urine culture and sensitivity testing, antibacterial therapy should be based on sensitivity results. Treatment with the appropriate antibacterials generally is performed for 2 to 3 weeks or for 4 to 6 weeks if pyelonephritis is suspected based on the physical examination, complete blood cell count, biochemistry profile, and abdominal ultrasonography. Routine monitoring of cats predisposed to UTIs by use of urine culture is recommended. As many as 33% of cats with chronic renal failure can be expected to have or develop a UTI during the next 6 months to 1 year.

Special caution is warranted with the use of fluoroquinolones in treatment of cats with a UTI associated with chronic renal failure (CRF). Initial reports of sudden blindness in cats treated with enrofloxacin showed what seemed to be a dose-related effect in some cats treated with higher dosages [45]. Some cats treated with lower dosages also developed blindness, but the affected cats were found to have reduced renal function. After dosage recommendations were reduced to 5 mg/kg every 24 hours, reports of blindness decreased dramatically. Cats with renal dysfunction develop higher plasma concentrations of fluoroquinolones and their metabolites. Retinal toxicity of fluoroquinolones may be related to peak concentrations of drug, which favor enhanced tissue distribution. All fluoroquinolones demonstrate dose-dependent retinal toxicity at higher dosages. In cats with CRF and a UTI, a dosage of 3 mg/kg every 24 hours or 2.5 mg/kg every 12 hours is recommended to reduce the potential for retinal toxicity. In normal cats, the concentration of fluoroquinolones in urine is high and well above the minimum inhibitory concentration for most pathogens. In CRF, the

concentration of fluoroquinolones in urine is decreased, but the concentration achieved is still above the minimum inhibitory concentration for most uropathogens. Whether the reduced dosage regimen achieves tissue concentrations above the minimum inhibitory concentration for offending organisms in the kidney of cats with upper UTI is not known.

## **Urolithiasis**

The formation of uroliths depends on supersaturation of the urine with calcuogenic minerals. If supersaturation is sufficient and sustained, a nidus may form on which subsequent calculus may develop. The type of calculus formed is dependent on many factors, including renal excretion of minerals, pH of the urine, presence of promoters, absence of inhibitors, concomitant bacterial infections, and possibly underlying inflammation. Clinical signs associated with urolithiasis generally are similar to those of other LUTDs, but obstruction may occur if the stone becomes lodged in the urethra. This complication may occur in male and female cats but is much more common in male cats.

The diagnosis of urolithiasis includes a combination of abdominal palpation and urinary tract imaging. Routine abdominal radiography is helpful if the uroliths are large enough (>3 mm) and radiodense. Abdominal ultrasonography and double-contrast cystography are beneficial for the detection of stones that are small (<3 mm) or radiolucent. Care must be taken not to assume that urolithiasis is present based on occurrence of crystals in the urine sediment. Likewise, crystals in the urine typically are not the cause of lower urinary tract signs, and one should not equate the type of crystals seen with the type of urolith that may be present. Crystals may be present without disease, calculi may be present without crystals, and crystals of a different type may be present in cats with calculi of a specific type. Quantitative stone analysis is the only way to ascertain definitively the type of urolith present. If uroliths are present, however, the index of suspicion for a particular type is greatly increased when taking into account the urine pH, presence or absence of UTI, and crystal type. Definitive long-term treatment of urolithiasis depends on the type of calculus present. Medical dissolution may be attempted for urate and struvite calculi, but no protocol is available to dissolve calcium oxalate calculi. For large calculi or those that do not respond to dissolution protocols, surgical intervention often is required. Voiding urohydropulsion may be attempted for stones up to 5 mm in female cats and 1 to 2 mm in male cats. Using this technique in male cats may result in obstruction if the size of the uroliths is underestimated; thus, it should only be performed by clinicians familiar with the technique.

All calculi that are removed from a cat should be analyzed by a diagnostic laboratory using quantitative analysis to determine the specific type of urolith present. Quantitative analysis is especially useful if a mixed urolith (more than

one mineral) is present. Qualitative analysis should not be performed, because frequent false-positive and false-negative results occur and the relative contribution of the different crystalloids present is not determined.

### *Urate urolithiasis*

Urate urolithiasis accounted for approximately 6% of 20,343 calculi evaluated by the University of Minnesota [46]. Portosystemic vascular anomalies can contribute to urate urolithiasis in cats, but the exact pathogenesis in most affected cats remains unknown [47]. Several risk factors, such as UTI leading to increased urine ammonia, excessive dietary protein, and metabolic acidosis, have been noted. It is not possible to predict which cats ultimately will develop urate urolithiasis, however. The bladder is the most common site for urate calculi, but they also are found in the urethra and kidneys.

Urate calculi generally are radiolucent and are not detected on survey radiographs unless other mineral constituents are present. Double-contrast cystography and ultrasonography may be used to facilitate detection of these calculi. Prevention of urolith formation and dissolution of calculi may be attempted by combining diets that are low in nucleoproteins (containing purines) and by the addition of allopurinol. Allopurinol acts by inhibiting the enzyme xanthine oxidase, which is required for uric acid production. Use of allopurinol may increase the risk of xanthine urolithiasis in the cat, however. The recommended dosage for allopurinol in cats is 9 mg/kg/d [48]. If medical dissolution is unsuccessful, as is generally the case in urate urolithiasis secondary to portosystemic shunts, surgical removal or urohydropulsion may be necessary. Correction of the portosystemic shunt, if present, should prevent recurrence.

### *Struvite urolithiasis*

Struvite calculi analyzed at two major laboratories performing quantitative analysis far outnumbered oxalate uroliths before the late 1980s. Since that time, possibly as a result of a shift by the pet food industry to magnesium-restricted acidifying diets, struvite calculi have declined to approximately 42%, whereas oxalates have increased to approximately 46% of the calculi analyzed [47]. The urine is sterile in approximately 95% of cases of struvite urolithiasis in cats, which is in sharp contrast to the situation in dogs, in which struvite urolithiasis is almost always associated with a bacterial UTI. Consequently, struvite urolithiasis in the cat is thought to be metabolic in origin. Struvite urolithiasis associated with a UTI generally is caused by the presence of urease-producing bacteria. Urease production results in an increase in urine pH that favors struvite crystallization in supersaturated urine. Struvite urolithiasis not associated with a bacterial UTI often is associated with concentrated urine and possibly with excess consumption and excretion of calculogenic minerals (especially magnesium) and alkaline urine.



A diagnosis of struvite urolithiasis is definitively made by quantitative stone analysis. Urinalysis and urine culture and sensitivity testing are indicated in cats with suspected struvite urolithiasis to determine the underlying etiology. Struvite uroliths usually are identified on plain abdominal radiographs because they are radiopaque and generally easily seen. If the calculi are extremely small, ultrasonography and double-contrast cystography may be required to identify them.

Treatment of struvite urolithiasis can include surgical removal of calculi, voiding urohydropulsion, or medical calculolysis depending on the individual situation. Increasing water intake is imperative in medical management of urolithiasis to promote formation of urine that is not supersaturated with calculogenic minerals. One commercially available calculolytic diet (Hills s/d, Science Diet, Topeka, KS) specifically designed for cats is acidifying, magnesium restricted, and supplemented with salt and has been reported to be effective in cats fed the canned preparation. Unlike the similar calculolytic diet for dogs, the formulation devised for cats is not restricted in protein. While feeding a calculolytic diet, it is important to emphasize to the owner that no other foods, including treats, should be given. The goal is to achieve a urine pH less than 6.3 and USG less than 1.030. During therapy, abdominal radiographs should be re-evaluated at 3-week intervals to ensure that therapy is working. In cats in which concomitant bacterial UTI is present, appropriate antibiotics should be given during dissolution and for 2 weeks after uroliths are no longer apparent radiographically. The average time for dissolution of struvite calculi in cats without infection was 36 days (range: 14–141 days), and in those with UTI, it was 44 days (range: 14–92 days) [49]. If uroliths persist or increase in size despite adequate dissolution therapy, the initial diagnosis must be questioned or the possibility of a mixed urolith should be considered. Occasionally, medical dissolution can be used to decrease the size of calculi so that voiding urohydropulsion can be employed.

After clinical signs have abated and dissolution is complete, routine monitoring by urinalysis and abdominal radiography may be indicated. In cats predisposed to bacterial UTIs (ie, those with chronic renal failure, diabetes mellitus, or perineal urethrostomy), periodic urine cultures are warranted. In all cats that repeatedly form uroliths, regardless of type, decreasing USG by feeding canned cat foods is indicated if the cat can be successfully transitioned to a moist diet. Many commercial diets have been designed to prevent formation of new struvite stones, but no reports confirm the effectiveness of any of these diets.

### *Oxalate urolithiasis*

Calcium oxalate uroliths have become the most frequent type of urolith in cats based on calculi submitted to laboratories for quantitative analyses. The percentage of uroliths from cats analyzed at the University of

Minnesota Urolith Center that were oxalates increased from approximately 2% to more than 40% over an 11-year period [50]. This shift may have been associated with a change in diet formulation by the pet food industry in an attempt to decrease the formation of sterile struvite uroliths by decreasing the magnesium and increasing the acid content of the diets. This strategy could have uncovered a group of cats predisposed to calcium oxalate stone formation not previously identified because they had not been exposed to a provocative environment. Calcium oxalate urolithiasis generally occurs in older cats (7–10 years of age) [51], frequently recurs, and generally is not associated with a bacterial UTI. Breeds that have been reported to be at an increased risk for calcium oxalate uroliths include the Ragdoll, British Shorthair, Foreign Shorthair, Himalayan, Havana Brown, Scottish Fold, Persian, and Exotic Shorthair. Birman, mixed-breed, Abyssinian, and Siamese cats have been reported to have a lower risk for developing calcium oxalate uroliths [51]. Indoor housing also has been reported as a risk factor for calcium oxalate urolithiasis [52]. This risk factor may be a consequence of decreased voiding and water intake.

Other than the previously mentioned dietary factors, the etiology of calcium oxalate urolith formation generally is unknown. Systemic metabolic derangements, such as acidosis and hypercalcemia, seem to increase the risk, however. Systemic acidosis results in release of calcium carbonate from bone (a normal buffering response) and secondary calciuresis. Acidosis also may decrease the urinary excretion of citrate, an inhibitor of calcium oxalate urolith formation. All cats that are presented with calcium oxalate urolithiasis should have their serum calcium concentration evaluated. Systemic hypercalcemia results in increased calciuresis and may increase the risk of urolith formation. As many as 35% of calcium oxalate stone-forming cats evaluated at the University of Minnesota Urolith Center have been noted to have hypercalcemia [50]; many of these cats likely had idiopathic hypercalcemia. If the hypercalcemia is not corrected, it is likely that calcium oxalate urolithiasis will recur.

Currently, no medical dissolution protocol is available for calcium oxalate calculi. If the uroliths are not voided and clinical signs are present, voiding urohydropulsion or surgical intervention is indicated. After surgical removal, a nonacidifying diet that is low in calcium and oxalate should be fed. Phosphorus should not be restricted because of the potential for increased gut absorption of calcium and secondary calciuresis arising as a result of low serum phosphorus concentration, and magnesium should not be restricted because of its inhibitory effect on oxalate urolith formation. Excessive supplementation with sodium to stimulate water consumption is not indicated because of potential augmentation of calciuresis. Potassium citrate (100–150 mg/kg/d) may be helpful in decreasing recurrence because of the inhibitory effects of citrate on calcium oxalate stone formation and its alkalinizing effect. This effect assumes that some of the administered citrate will be excreted unmetabolized into the urine. Reports documenting the

effectiveness of this treatment are lacking, however. Increasing water consumption by feeding canned food if possible is paramount in the management of urolithiasis.

Several commercially available diets have been developed that are designed to prevent recurrence of calcium oxalate calculi. No evidence-based outcome studies have been reported showing the effectiveness of any of these diets to prevent recurrent urolith formation. These diets have been developed based on the assumption that less urinary acidification is beneficial. Some companies have data indicating that dietary changes alter the relative supersaturation or activity product ratio of urine from normal cats fed these diets. Relative supersaturation and activity product ratio data provide surrogate information about the possibility of decreasing recurrence of urolithiasis in clinically affected cats.

### *Urethral obstruction*

The most common cause of urethral obstruction in male cats was urethral plugs in one study [5] and idiopathic disease in a more recent report [53]. When evaluated with fiberoptic urethroscopy, plugs were identified in approximately 30% of obstructed cats in a preliminary study at The Ohio State University (K.L. Cannizzo, DVM, MS; D.J. Chew, DVM, unpublished observations). Other potential causes include urolithiasis with or without a bacterial UTI, urethral spasm, and, rarely, stricture or neoplasia. Male cats are greatly predisposed to urethral obstruction compared with female cats because of their extremely narrow penile urethra (Fig. 7). Large (>5 mm) uroliths cause obstruction of the female urethra, however.

The exact pathogenesis of urethral plugs has not been definitively proven. One theory is that the occurrence of UTI or inflammation with crystalluria leads to the aggregation of protein, crystals, WBCs, and red blood cells, which, in turn, are surrounded by amorphous material, leading to plug formation. Another theory suggests that chronic bladder inflammation leads to a decrease in vascular integrity. Loss of vascular integrity then leads to an increase in urine protein concentration, increased urine pH, crystalluria, and, ultimately, plug formation. Urethritis without plug formation is severe in some cats with urethral obstruction examined by urethroscopy. It is not known what role, if any, calicivirus-like particles seen by electron microscopy of urethral plugs play in the pathogenesis of urethral plug development. Any plug that is obtained after re-establishment of patency should be evaluated for composition by quantitative analysis. Urethral plugs generally are composed of struvite crystals. This observation continues to be true, despite the increased frequency of calcium oxalate calculi and, presumably, calcium oxalate crystalluria.

At presentation, an obstructed cat should be treated on an emergency basis. Cats that have been obstructed for more than 48 hours are most likely to be severely ill and require uremic crisis management. Placement of an

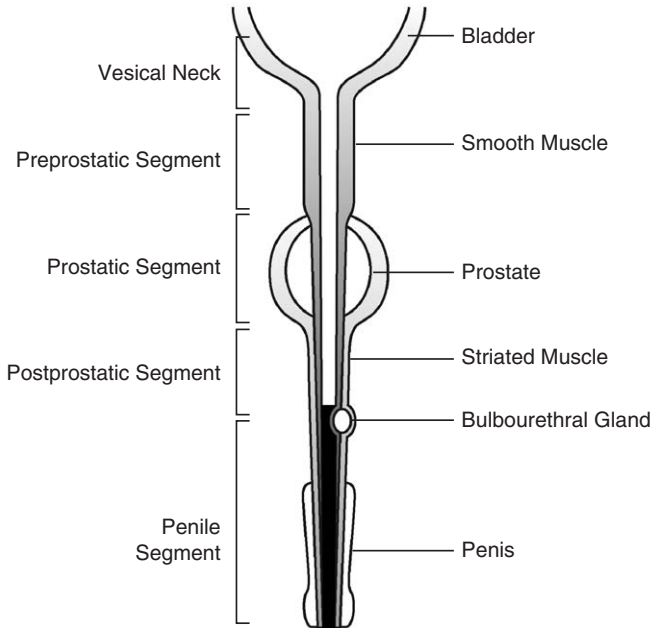


Fig. 7. Diagram of the lower urinary tract of a male cat. Notice the thin circumference of the urethra as it leaves the bladder. This narrow urethra can easily be obstructed secondary to inflammation, calculi, and urethrosperm.

intravenous catheter and administration of analgesic medication should be performed at presentation. Decompressive cystocentesis may be advisable before re-establishing urethral patency. Cystocentesis can be performed with a single puncture into the bladder using a 22- or 23-gauge butterfly needle or a 22-gauge needle attached to an extension set, stopcock, and syringe. The needle is inserted halfway between the apex and neck of the bladder, and all the urine that can be obtained is removed. More complete removal of urine is accomplished when digital compression is maintained on the bladder wall. Some leakage of urine into the abdomen accompanies this procedure but is minimized by more complete evacuation of urine from the bladder.

Laboratory evaluation, including a complete blood cell count, serum biochemistry, urinalysis, and urine culture, should be performed in all obstructed cats. Obstructed cats may have life-threatening dehydration, hyperkalemia, acidosis, or hypocalcemia that may need to be corrected. Hyperkalemia and acidosis generally resolve adequately with volume expansion using a balanced electrolyte solution. The use of calcium salts, glucose, or glucose and insulin may be required to correct hyperkalemia in some instances. In a recent study of 223 obstructed cats, serum potassium concentration was evaluated in 199. Twelve percent of these 199 cats had mildly increased serum potassium concentrations ( $\geq 6.0$  mEq/L and  $< 8.0$

mEq/L), 11.6% had potassium concentrations greater than or equal to 8.0 mEq/L and less than 10.0 mEq/L, and 0.5% had serum potassium concentrations greater than 10.0 mEq/L [54]. One study reported a 75% frequency of ionized hypocalcemia in cats with urethral obstruction [55]. The presence of severe metabolic acidosis as determined by blood gas analysis (pH <7.1) may necessitate sodium bicarbonate administration.

Establishment of urethral patency is obtained after the patient is stabilized and properly sedated or anesthetized based on its clinical condition and overall stability. During establishment of patency, the penis should be handled gently to avoid aggravating inflammation. After sedation and gentle penile manipulation or massage, a urethral plug or extremely small calculi contributing to the obstruction may be expelled. All cats that are presented with urethral obstruction may not need placement of an indwelling urinary catheter depending on the quality of the urethral stream and presence or absence of systemic illness. If the animal is moribund, has a severely large bladder, or has severe azotemia or other metabolic derangements, catheter placement is essential for adequate patient management.

Marked postobstructive diuresis may occur in cats that were obstructed for several days or are severely azotemic. The degree of postobstructive diuresis is often proportional to the degree of azotemia. A balanced electrolyte solution, such as lactated Ringer's solution or Plasmalyte, often is adequate for rehydration and stabilization. Urine output should be monitored to ensure that dehydration does not occur because of the magnitude of diuresis. Management of postobstructive diuresis by monitoring the patient's input and output ("ins and outs") may be needed. This procedure is accomplished by providing sensible and insensible fluid needs. Insensible losses cannot be measured and are generally considered to be 10 mL/lb/d. Sensible losses are losses, such as urine, that can be easily measured. The insensible loss replacement is kept constant, and the sensible losses generally are measured for a given period (eg, 2–4 hours) and then replaced over the following time interval. Fluids may be gradually tapered after azotemia resolves. After the cat is stabilized and while the catheter is still in place, acepromazine (0.02–0.05 mg/kg every 4–6 hours) and buprenorphine (5–20 µg/kg) or butorphanol (0.2–0.4 mg/kg every 6–8 hours) can be administered in cats with urethral obstruction. These medications aid in relaxing the urethral sphincter and provide pain relief.  $\alpha_1$ -Antagonists, such as phenoxybenzamine (2.5–7.5 mg every 12–24 hours) and prazosin (0.5 mg every 8 hours), may be added to decrease urethral tone as an alternative to acepromazine. In animals that have bladder atony secondary to severe prolonged distention of the bladder, parasympathomimetic drugs, such as bethanecol (1.25–5.0 mg every 12 hours) may be added once urethral patency has been established. After successful medical management, owner counseling about long-term medical treatment of FIC is necessary if it is suspected as the underlying cause. Fig. 8 depicts an approach to treatment of a severely obstructed cat on initial presentation.

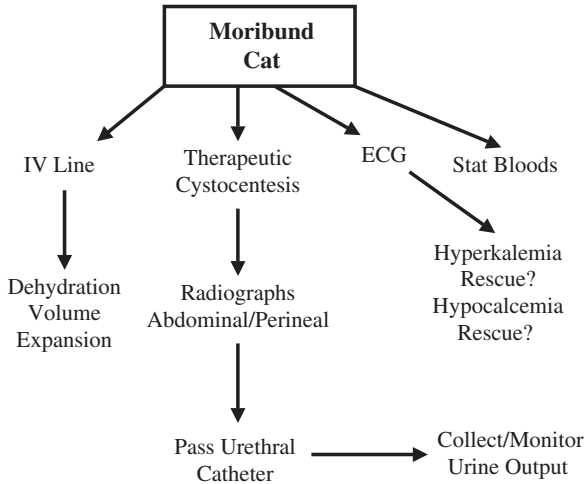


Fig. 8. Algorithm approach to an obstructed cat. Decompressive cystocentesis, fluid therapy, and baseline blood work (including blood gas analysis with electrolytes) should be performed at presentation. Obtaining patency of the urethra should be performed after other life-saving measures and diagnostics are completed.

If medical management fails despite exhaustive treatment or in recurrent severe episodes of urethral obstruction, perineal urethrostomy may be indicated. This surgery is used only in severely affected animals and only after extensive owner education about the potential complications, such as urinary incontinence and stricture formation (both of which are unlikely) and increased risk of ascending UTIs [56].

## References

- [1] Kirk H. Urinary deposits and retention. In: *The diseases of the cat and its general management*. London: Bailliere, Tindall and Cox; 1925. p. 261–7.
- [2] Willeberg P. Epidemiology of naturally-occurring feline urologic syndrome. *Vet Clin N Am Small Anim Pract* 1984;14:455–69.
- [3] Patronek GJ, Glickman LT, Beck AM, et al. Risk factors for relinquishment of cats to an animal shelter. *J Am Vet Med Assoc* 1996;209:582–8.
- [4] Lund EM, Armstrong PJ, Kirk CA, et al. Health status and population characteristics of dogs and cats examined at private veterinary practices in the United States. *J Am Vet Med Assoc* 1999;214:1336–41.
- [5] Kruger JM, Osborne CA, Goyal SM, et al. Clinical evaluation of cats with lower urinary tract disease. *J Am Vet Med Assoc* 1991;199:211–6.
- [6] Buffington CA, Chew DJ, Kendall MS, et al. Clinical evaluation of cats with nonobstructive lower urinary tract diseases. *J Am Vet Med Assoc* 1997;210:46–50.
- [7] Jones B, Sanson RL, Morris RS. Elucidating the risk factors of feline urologic syndrome. *NZ Vet J* 1997;45:100–8.
- [8] Bovee KC, Reif JS, Maguire TG, et al. Recurrence of feline urethral obstruction. *J Am Vet Med Assoc* 1979;174:93–6.
- [9] Barker J, Povey RC. The feline urolithiasis syndrome: a review and an inquiry into the alleged role of dry cat food in its aetiology. *J Small Anim Pract* 1973;14:445–57.

- [10] Bartges JW. Lower urinary tract disease in geriatric cats. In: Proceedings of the 15th American College of Veterinary Internal Medicine Forum; 1997. p. 322–4.
- [11] Sturgess CP, Hesford A, Owen H, et al. An investigation into the effects of storage on the diagnosis of crystalluria in cats. *J Feline Med Surg* 2001;3:81–5.
- [12] Scrivani PV, Chew DJ, Buffington CA, et al. Results of double-contrast cystography in cats with idiopathic cystitis: 45 cases (1993–1995). *J Am Vet Med Assoc* 1998;212:1907–9.
- [13] Scrivani PV, Chew DJ, Buffington CA, et al. Results of retrograde urethrography in cats with idiopathic, nonobstructive lower urinary tract disease and their association with pathogenesis. *J Am Vet Med Assoc* 1997;211:741–8.
- [14] de Groat WC, Yoshimura N. Pharmacology of the lower urinary tract. *Annu Rev Pharmacol Toxicol* 2001;41:691–721.
- [15] Buffington CA, Blaisdell JL, Binns SP Jr, et al. Decreased urine glycosaminoglycan excretion in cats with interstitial cystitis. *J Urol* 1996;155:1801–4.
- [16] Byrne DS, Sedor JF, Estojak J, et al. The urinary glycoprotein GP51 as a clinical marker for interstitial cystitis. *J Urol* 1999;161:1786–90.
- [17] Buffington CA, Chew DJ, Woodworth BE. Animal model of human disease—feline interstitial cystitis. *Comp Pathol Bull* 1997;29:3, 6.
- [18] Lavelle JP, Meyers SA, Ruiz WG, et al. Urothelial pathophysiological changes in feline interstitial cystitis: a human model. *Am J Physiol Renal Physiol* 2000;278(Suppl):F540–53.
- [19] Gao X, Buffington CA, Au JL. Effect of interstitial cystitis on drug absorption from the urinary bladder. *J Pharmacol Exp Ther* 1994;271:818–23.
- [20] Reche AJ, Buffington CA. Increased tyrosine hydroxylase immunoreactivity in the locus coeruleus of cats with interstitial cystitis. *J Urol* 1998;159:1045–8.
- [21] Welk K, Buffington CA. Effects of interstitial cystitis on central neuropeptide and receptor immunoreactivity in cats. Columbus: The Ohio State University; 2003. p. 31.
- [22] de Groat WC, Booth AM, Yoshimura N. Neurophysiology of micturition and its modification in animal models of human disease. In: Maggi CA, Hill CE, editors. *Nervous control of the urogenital system. The autonomic nervous system*. Chur: Harwood; 1993. p. 227–90.
- [23] Buffington CA, Pacak K. Increased plasma norepinephrine concentration in cats with interstitial cystitis. *J Urol* 2001;165:2051–4.
- [24] Stevens CW, Brenner GM. Spinal administration of adrenergic agents produces analgesia in amphibians. *Eur J Pharmacol* 1996;316:205–10.
- [25] Sabbe MB, Penning JP, Ozaki GT, et al. Spinal and systemic action of the alpha 2 receptor agonist dexmedetomidine in dogs. Antinociception and carbon dioxide response. *Anesthesiology* 1994;80:1057–72.
- [26] Petrovaara A, Kauppila T, Jyvasjarvi E, et al. Involvement of supraspinal and spinal segmental alpha-2-adrenergic mechanisms in the medetomidine-induced antinociception. *Neuroscience* 1991;44:705–14.
- [27] Westropp JL, Buffington CA. Evaluation of the hypothalamic-pituitary-adrenal axis in cats with FIC. Presented at 15th Annual American College of Veterinary Internal Medicine Forum. American College of Veterinary Internal Medicine; 2003.
- [28] Westropp JL, Welk K, Buffington CA. Small adrenal glands in cats with feline interstitial cystitis. *J Urol* 2002;170:2492–7.
- [29] Chew DJ, Buffington CA, Kendall MS, et al. Amitriptyline treatment for severe recurrent idiopathic cystitis in cats. *J Am Vet Med Assoc* 1998;213:1282–6.
- [30] Neilson JC. Feline house soiling: elimination and marking behaviors. *Vet Clin N Am Small Anim Pract* 2003;33:287–301.
- [31] Overall KL. Feline elimination disorders. In: Overall KL, editor. *Clinical behavioral medicine for small animals*. St. Louis: Mosby; 1997. p. 160–94.
- [32] Delzio S, Ribarich C. *Feline*. New York: Harper Perennial; 1999.
- [33] McCune S. Environmental enrichment for cats—a review. Second International Conference on Environmental Enrichment, 1997.

- [34] Turner DC. The human-cat relationship. In: Bateson P, editor. *The domestic cat—the biology of its behavior*. 2nd edition. Cambridge: Cambridge University Press; 2000. p. 194–206.
- [35] Markwell PJ, Buffington CA, Chew DJ, et al. Clinical evaluation of commercially available urinary acidification diets in the management of idiopathic cystitis in cats. *J Am Vet Med Assoc* 1999;214:361–5.
- [36] Griffith CA, Steigerwald ES, Buffington CA. Effects of a synthetic facial pheromone on behavior of cats. *J Am Vet Med Assoc* 2000;217:1154–6.
- [37] Mills DS, White JC. Long-term follow up of the effect of a pheromone therapy on feline spraying behaviour. *Vet Rec* 2000;147:746–7.
- [38] Hunthausen W. Evaluating a feline facial pheromone analogue to control urine spraying. *Vet Med* 1998;143:151–6.
- [39] Pena F, Neaga E, Amuzescu B, et al. Amitriptyline has a dual effect on the conductive properties of the epithelial Na channel. *J Pharm Pharmacol* 2002;54:1393–8.
- [40] Kruger JM, Conway TS, Kaneene JB, et al. Randomized controlled trial of the efficacy of short-term amitriptyline administration for treatment of acute, nonobstructive, idiopathic lower urinary tract disease in cats. *J Am Vet Med Assoc* 2003;222:749–58.
- [41] Kraijer M, Fink-Grimmels J, Nickel RF. The short-term clinical efficacy of amitriptyline in the management of idiopathic feline lower urinary tract disease: a controlled clinical study. *J Feline Med Surg* 2003;5(3):191–6.
- [42] Center SA, Elston TH, Rowland PH, et al. Fulminant hepatic failure associated with oral administration of diazepam in 11 cats. *J Am Vet Med Assoc* 1996;209:618–25.
- [43] Freitag T, Squires RA, Schmid J, et al. Antibiotic sensitivity profiles underestimate the proportion of relapsing infections in cats with chronic renal failure and urinary tract infection [abstract 10]. Presented at the American College of Veterinary Medicine Forum. Minneapolis, June 9–12, 2004.
- [44] Lulich JP, Osborne CA, O'Brien TD, et al. Feline renal failure: questions, answers, questions. *Compend Contin Educ Pract Vet* 1992;14:127–53.
- [45] Gelatt KN, van der Woerd A, Ketring KL, et al. Enrofloxacin-associated retinal degeneration in cats. *Vet Ophthalmol* 2001;4(2):99–106.
- [46] Osborne CA, Kruger JM, Lulich J, et al. Feline lower urinary tract diseases. In: Ettinger SJ, Feldman E, editors. *Textbook of veterinary internal medicine*. Philadelphia: WB Saunders; 2000. p. 1710–47.
- [47] Duval D, Barsanti JA, Cornelius LM, et al. Ammonium acid urate urolithiasis in a cat. *Feline Pract* 1995;23:18–22.
- [48] Plumb DC. Allopurinol. In: *Plumb veterinary drug handbook*. 4th edition. Ames: Iowa State University Press; 2002. p. 20.
- [49] Osborne CA, Lulich JP, Kruger JM, et al. Medical dissolution of feline struvite urocystoliths. *J Am Vet Med Assoc* 1990;196:1053–63.
- [50] Osborne CA, Lulich JP, Thumachi R, et al. Feline urolithiasis. Etiology and pathophysiology. *Vet Clin N Am Small Anim Pract* 1996;26:217–32.
- [51] Lekcharoensuk C, Lulich JP, Osborne CA, et al. Association between patient-related factors and risk of calcium oxalate and magnesium ammonium phosphate urolithiasis in cats. *J Am Vet Med Assoc* 2000;217:520–5.
- [52] Kirk CA, Ling GV, Franti CE, et al. Evaluation of factors associated with development of calcium oxalate urolithiasis in cats. *J Am Vet Med Assoc* 1995;207:1429–34.
- [53] Gerber B. Short-term followup of cats with obstructive lower urinary tract disease. In: *Proceedings of the 13th European Congress of Veterinary Internal Medicine*. Uppsala; 2003.
- [54] Lee JA, Drobatz KJ. Characterization of the clinical characteristics, electrolytes, acid-base, and renal parameters in male cats with urethral obstruction. *J Vet Emerg Crit Care* 2003; 13:227–33.
- [55] Drobatz KJ, Hughes D. Concentration of ionized calcium in plasma from cats with urethral obstruction. *J Am Vet Med Assoc* 1997;211:1392–5.
- [56] Smith CW. Perineal urethrostomy. *Vet Clin N Am Small Anim Pract* 2002;32(4):917–25.